

Testp

[See online here](#)



Classification of Cranial Nerves

Every cranial nerve (CN) is assigned a Roman numeral as a name. The numbering is based on the order in which the CN emerges from the brain, from ventral to dorsal. **The name indicates the function or the course.**

List of CNs

- I Olfactory
- II Optic
- III Oculomotor
- IV Trochlear
- V Trigeminal
- VI Abducens
- VII Facial
- VIII Vestibulocochlear
- IX Glossopharyngeal
- X Vagus
- XI Accessory
- XII Hypoglossal

Following is a mnemonic to remember the names of the CNs: **ooh, ooh, ooh to touch and feel very good velvet. Always heavenly!**

How do the CNs differ in terms of fibers?

The 12 pairs of CNs originate from the nose (CN I), the eyes (CN II), the inner ear (CN VIII), the brainstem (CN III-XII), and the spinal cord (part of XI).

CNs have **sensory (afferent) and motor (efferent) functions**. CN I and CN II convey sensory information. The olfactory and optic nerves arise from the cerebrum and diencephalon, respectively.

All the other CNs originate from the brainstem nuclei (the hypoglossal nerve is located at the border of the spinal cord) and include sensory axons as well as motor axons. The oculomotor nerve (III) and the trochlear nerve (IV) emerge from the mesencephalon. The CNs V to XII originate from the pons (bridge) and the medulla oblongata (extended spinal cord).

The CNs III, IV, VI, XI, and XII are mainly motor nerves and provide innervation of the skeletal muscles. However, the CNs I and II mentioned before and the

vestibulocochlear nerve are purely sensory, but there are also CNs (CN V, VII, IX, X) that are both sensory and motor nerves.

For this reason, you should **memorize** the following **sentence**: (s = sensory, m = motor, b = both):

Some students make money, but my brother says Boris Becker makes more.

The oculomotor nerve, the facial nerve, the glossopharyngeal nerve, and the vagus nerve also include somatic and autonomic axons. The **somatic part ensures the innervation of the skeletal muscles** and the **autonomic part belonging to the parasympathetic nervous system** innervates the glands, the smooth muscles, and the cardiac muscle.

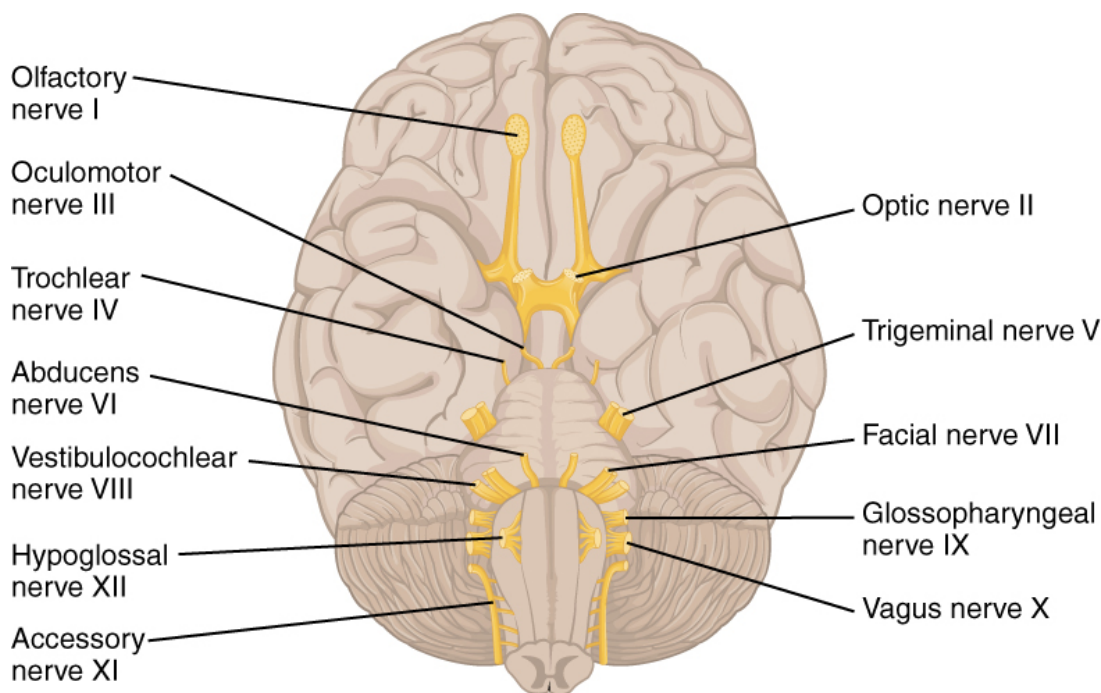


Image: 'The Cranial Nerves' by Phil Schatz. License: [CC BY 4.0](https://creativecommons.org/licenses/by/4.0/).

A short overview of the CNs I—VI

Watch the next lecture: [Cranial Nerve I: Olfactory Nerve](#).

CN I: Olfactory Nerve

Quality and course

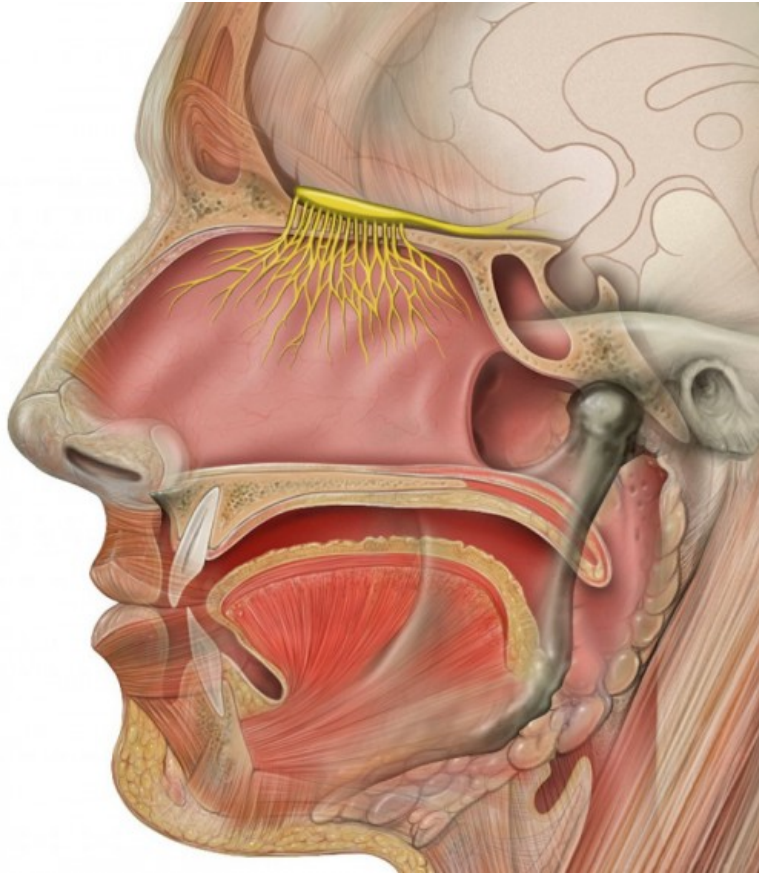


Image: "Head Anatomy with Olfactory Nerve" by Patrick J. Lynch. License: [CC BY 2.5](https://creativecommons.org/licenses/by/2.5/)

The olfactory nerve is **part of the olfactory pathway and is a purely sensory nerve**. The olfactory mucosa, with its olfactory cells, is located in the superior nasal meatus (meatus nasi superius).

The olfactory cells are nerve cells in which the unmyelinated axons are bundled and emerge through the **openings of the cribriform plate (lamina cribrosa, part of the ethmoid bone)** and the **dura mater located on top** into the anterior cranial fossa. The approximately **40 bundles** make up the right and the left olfactory nerve.

The olfactory nerve is the shortest nerve that does not travel via the brainstem. The olfactory nerves end in the brain in two paired masses of **grey matter and the olfactory bulb**, where they are switched to the second neuron. The axon terminals (synaptic knobs) of the olfactory receptors (olfactory cells) compose the next neurons on the olfactory pathway in the respective bulb synapses with dendrites and soma.

These axons that emerge from the neurons of the olfactory bulb are located in the olfactory tract, which leads to the **olfactory cortex (rhinencephalon/smell brain)**, where the olfactory sensation is perceived and then is linked to emotions.

Function of the olfactory nerve

- It functions to transmit smells and more advanced aspects of taste.

CN II: Optic Nerve

Quality and course

The optic nerve is the **visual nerve (optikos = vision) and it is purely sensory in function. The optic nerve is formed by the convergence of axons from the retinal ganglion cells. These cells, in turn, receive impulses from the photoreceptors of the eye.** For the most part, the optic nerve is encased in the three meninges. From the retina of the eye, the visual impulses are transmitted to the diencephalon via the optic nerve. **Fibers** pass from the visual center of the thalamus **to the occipital visual cortex**, where the image of the event is created.

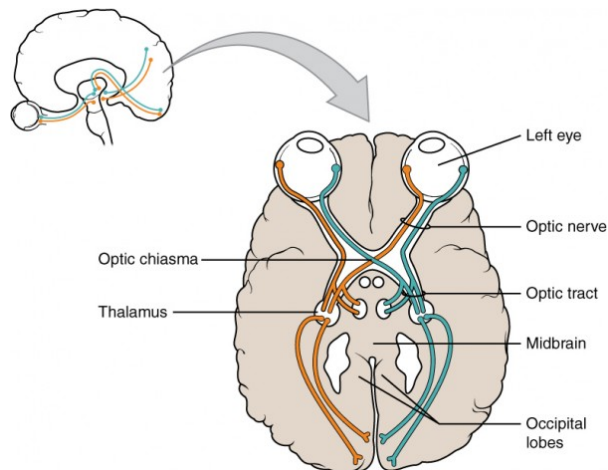


Image: 'Optic Nerve vs Optic Tract' by OpenStax College.
License: [CC BY 3.0](https://creativecommons.org/licenses/by/3.0/).

However, both of the optic nerves do not run separately to their ipsilateral part of the thalamus. In the part of the **sphenoid bone, the sella turcica (Turkish chair), they join into the optic decussation (chiasma opticum)**. There, the fibers of both of the optic nerves mix until new fiber tracts form and continue to the diencephalon. As for the chiasma, the nerve bundles are not called nerves any longer, but **optic tracts**.

The transmission of the field of vision leads to a mixture of fibers. In the optic tract, the part of the optic nerve transmitting the **lateral (temporary) field of vision** proceeds on **the same side**. In the optic decussation, the **medial parts** of the field of vision are switched to the contralateral side and cross to the **opposite side**.

Function of the optic nerve

- It functions to transmit visual information from the retina to the vision centers of the brain through electrical impulses.

CN III: Oculomotor Nerve

Quality and course

The oculomotor nerve (oculus= eye) is a **mixed CN that is mainly motor**, while the motor nucleus is located in the **ventral mesencephalon**. It innervates most of the outer (extraocular) eye muscles and **passes from the midbrain (mesencephalon) to the**

bony eye socket (orbit).

It extends ventrally and divides into a superior branch and an inferior branch. The rectus superior muscle (one of the outer eye muscles) and the levator palpebrae superioris muscle (muscle of the upper eyelid) are innervated by the axons of the superior branch of the oculomotor nerve. The rectus medialis muscle, the rectus inferior muscle, and the obliquus inferior muscle, which are all outer eye muscles, are supplied by the axons of the inferior branch.

Function of the motor axons

- They function to transmit movement of the upper eyelid and the eye.

The oculomotor nerve serves the voluntary motor function, but it also contains parasympathetic fibers.

The inferior branch serves the parasympathetic innervation of the inner eye muscles and contains the ciliary muscle and the iris sphincter muscle. Parasympathetic impulses, reaching the ciliary ganglion, originate from the oculomotor nucleus in the mesencephalon, which is the 'circuit center' of the autonomous nervous system.

Function of the parasympathetic axons

Parasympathetic axons extend from the ciliary ganglion to the ciliary muscle, which is responsible for the following:

- Accommodation (adaption to the distance of an object)

Further parasympathetic fibers serve the following:

- The stimulation of the iris sphincter muscle (constriction of the pupil in bright light)
- The stimulation of the iris dilator muscle (dilatation of the pupil)

Function of the sensory axons

- Their function is proprioception (part of self-perception).

The sensory part consists of afferent neurons of the proprioceptors of the outer eye muscles toward the mesencephalon. These **axons bring together information about the non-visual perception** of body movement and position in space (proprioception), as well as the location and position of single body parts to each other. It controls the muscles that allow for visual tracking and fixation by the eye. Visual tracking is the ability to follow an object as it moves across the field of vision.

CN IV: Trochlear Nerve

Quality and course

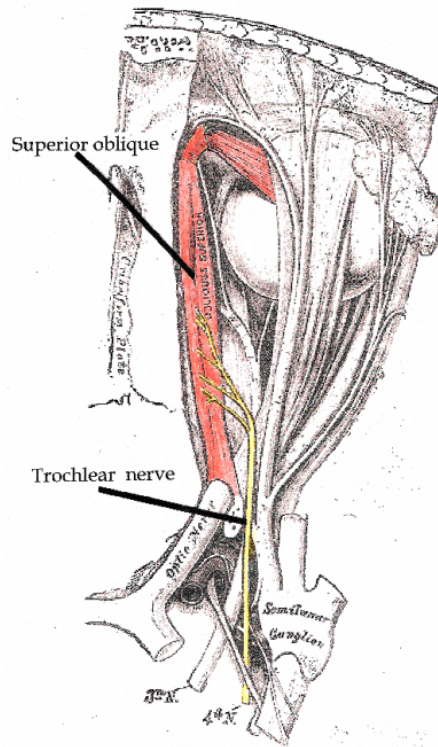


Image: 'Trochlear Nerve' by Btarski. License: [CC BY-SA 3.0](https://creativecommons.org/licenses/by-sa/3.0/).

The trochlear nerve is the **smallest of the 12 CNs and is the only nerve exiting the dorsal aspect of the brainstem with mostly motor axons**. The trochlear nerve arises from the trochlear nucleus of the brain, emerging from the posterior aspect of the midbrain. It is the only CN to exit from the posterior midbrain.

Beneath the tectum of the mesencephalon (quadrigeminal plate), the nerve exits the midbrain (mesencephalon) and, as the olfactory nerve, it passes through the wall of the cavernous sinus.

Function of the trochlear nerve

Somatomotor functions include the following:

- Eye movement and innervation of the obliquus superior muscle

Sensory functions include the following:

- **Proprioception**

CN V: Trigeminal Nerve

Quality and course

The trigeminal nerve is a **mixed CN with mainly sensory parts. It is regarded as the largest CN**. It runs from the pons to the petrous portion (pars petrosa) of the temporal bone (Os temporale), where it converges the trigeminal ganglion. As the name suggests, **the trigeminal nerve has three major branches** consisting of nerve cell clusters:

- Ophthalmic nerve
- Maxillary nerve
- Mandibular nerve

The ophthalmic nerve passes through the superior orbital fissure. It is the smallest branch. The maxillary nerve is located between the ophthalmic nerve and the mandibular nerve. It is a medium-sized nerve that passes through the foramen rotundum. The mandibular nerve passes through the oval foramen and is the largest of the three trigeminal branches.

Function of the trigeminal nerve

The sensory functions of the trigeminal nerve are the **transmission of impulses for touch, pain, temperature, proprioception, and the somatomotor function** with mandibular movement.

The **ophthalmic nerve (V1)** has mainly sensory fibers and has the following functions:

- Sensory innervation of the skin of the forehead, the eyes, the nose, and the nasal mucosa
- Innervation of the iris, the cornea, the conjunctiva, and the lacrimal gland
- Supply of the skin of the forehead and transmission of pressure pain at the exit point of the supraorbital foramen

The **maxillary nerve (V2)** innervates the facial skin with sensory fibers and a parasympathetic part and has the following tasks:

- Supply of the lower eyelid, its conjunctiva, and the upper lip
- Supply of the teeth (upper molar, incisor, and canine), nasal cavity gums of the upper jaw and the palate mucosa (including the uvula), and tonsils
- Supply of the lacrimal gland and nasal glands by the parasympathetic part

In addition to the sensory fibers, the **mandibular nerve** also contains motor fibers of the trigeminal nerve. It has the following tasks:

- Innervation of all the muscles of mastication (e.g., masseter muscle) and the suprahyoid muscles by the motor fibers
- Supply of the teeth (lower molar, incisor, and canine teeth), the gums of the lower jaw, the buccal mucosa, the dorsum of the tongue, and the external acoustic meatus, including the eardrum, by the sensory fibers

CN VI: Abducens Nerve

Quality and course

The abducens nerve **arises from the abducens nucleus of the pons (bridge) and is one of the mixed CNs with mainly motor fibers**. From the nucleus, the axons emerge to the rectus lateralis muscle (outer eye muscle), pass through the superior orbital fissure, and end in the orbit.

Function of the abducens nerve

Somatomotor functions include the following:

- Eye movement and abduction of the eyes

Sensory functions include the following:

- Proprioception

A short overview of the CNs VII-XII

Watch the next lecture: [Cranial Nerve VII: Facial Nerve.](#)

CN VII: Facial Nerve

Quality and course

The facial nerve is a **mixed CN with motor, sensory, and parasympathetic parts**. The sensory axons extend from the taste buds of the anterior two-thirds of the tongue through the geniculate ganglion, to the pons (bridge). Somatomotor neurons, on the other hand, originate from a nucleus of the pons and pass through the temporal bone.

The axons of the parasympathetic neurons of the facial nerve end in the two parasympathetic ganglions (pterygopalatine ganglion and submandibular ganglion).

Function of the facial nerve

The facial nerve has **mainly motor functions**. However, a part of its fibers, which is called an intermediate nerve, has sensory functions.

Motor functions include the following:

- Innervation of the entire mimic facial musculature (platysma and muscles of the auricle)
- Eyelid movement and closing of the eye by the orbicularis oculi muscle
- Movement and closing of the mouth by the orbicularis oris muscle
- Precise adjustment of the auditory ossicles by the stapedius muscle
- Movement of the mandible by the mentalis muscle

Sensory and parasympathetic functions include the following:

- Sense of taste in the anterior two-thirds of the tongue
- Innervation of the three large salivary glands, the lacrimal glands, and the nasal glands
- External acoustic meatus

CN VIII: Vestibulocochlear Nerve

Quality and course

The vestibulocochlear nerve is a **mainly sensory nerve** that has its nucleus in the pons and passes together with the facial nerve to the internal acoustic meatus. There, it **splits into two divisions**:

- Vestibular nerve
- Cochlear nerve

In the vestibular nerve, the sensory fibers of the semi-circular canal, the saccule and the utricle of the inner ear, pass to the vestibular ganglion ending in the vestibular nuclei of

the pons.

Axons originating from the motor neurons project from the pons to the hair cells of the semi-circular canal, the saccule, and the utricle.

The sensory fibers, located in the cochlear ganglion and passing to the nuclei of the medulla oblongata, originate from the cochlear nerve in the organ of Corti (spiral organ) located in the cochlea of the inner ear.

Axons of motor neurons extend from the pons to the hair cells of the spiral organ of Corti.

Function of the vestibulocochlear nerve

Functions of the vestibular nerve include the following:

- Regulation of the hair cells of the organ of Corti for the adjustment of sensitivity (spatial position)
- Transmission of impulses for the sense of balance, maintaining equilibrium

Functions of the cochlear nerve include the following:

- Regulation of the hair cells of the organ of Corti for the adjustment of sensitivity (regarding sound waves)
- Transmission of impulses for hearing

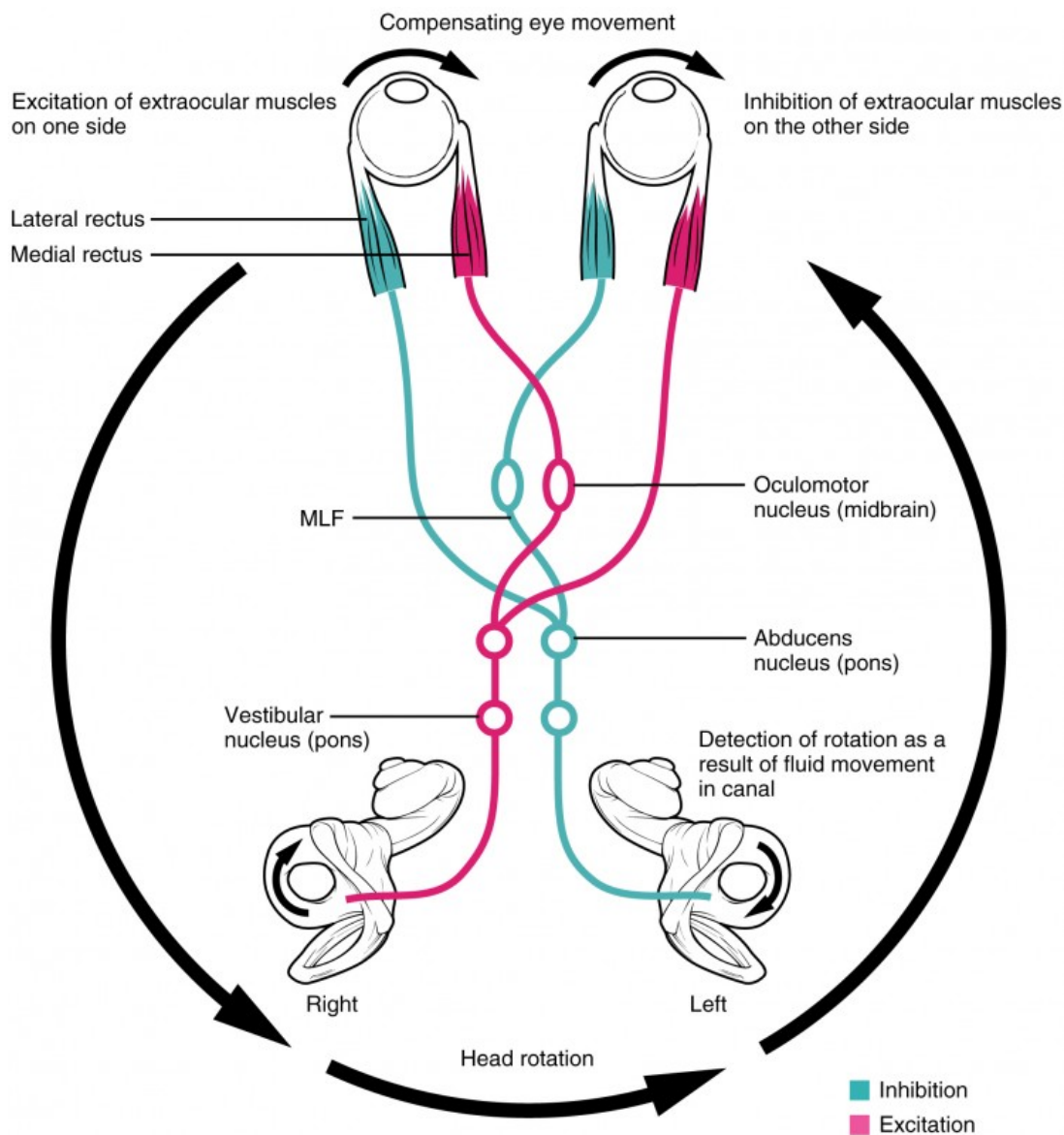


Image: 'Vestibulo-ocular Reflex' by Phil Schatz. License: [CC BY 4.0](https://creativecommons.org/licenses/by/4.0/).

CN IX: Glossopharyngeal Nerve

Quality and course

The glossopharyngeal nerve is a **mixed CN with motor, sensory, and parasympathetic fibers**. It exits the medulla oblongata behind the olivary bodies, together with the vagus nerve and the accessory nerve.

In the area of the posterior cranial fossa, the sensory fibers exit the cranial cavity and pass between the internal carotid artery and the internal jugular vein until they laterally reach the root of the tongue. The motor fibers pass through the jugular foramen from the nuclei of the medulla.

Function of the glossopharyngeal nerve

Motor functions include the following:

- Innervation of the palate muscles and the muscles of the pharynx by the vagus nerve
- Dilatation of the pharynx during swallowing and speaking

Sensory functions include the following:

- Innervation of the mucosa of the middle ear, the mastoid, and the eardrum
- Supply of the velum, including the palatine tonsil and the posterior third of the tongue
- Taste and somatic perception (touch, pain, and temperature) of the posterior third of the tongue
- Proprioception in the swallowing musculature
- Blood pressure regulation
- Regulation of the oxygen and carbon dioxide content of the blood for the control of ventilation

Parasympathetic functions include the following:

- Stimulation of salivation
- Carotid glomus—contains chemoreceptors responsible for the oxygen content, as well as pressure receptors that are important for the regulation of blood pressure

CN X: Vagus Nerve

Quality and course

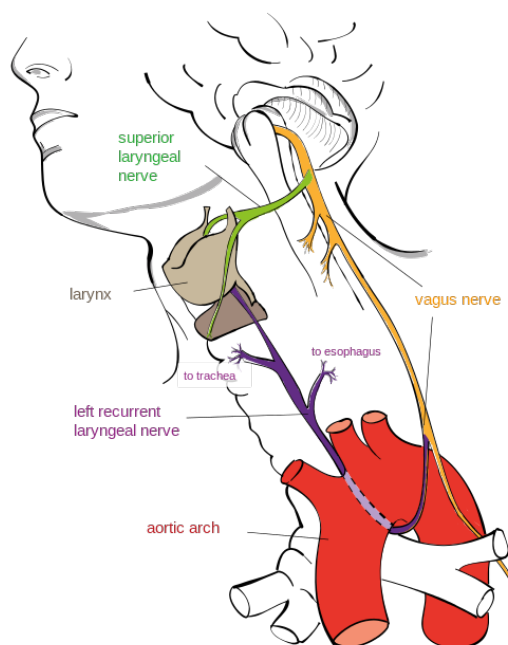


Image: 'Drawing of the Left Recurrent Laryngeal Nerve' by Jkwchui. License: [CC BY-SA 3.0](https://creativecommons.org/licenses/by-sa/3.0/).

The vagus nerve is the **parasympathetic main nerve that is responsible for large parts of the body** and innervates almost all of the organs of the thorax and the

abdomen. The vagus nerve has the longest course of all CNS.

After exiting the medulla oblongata, the vagus nerve passes through the skull base. Near the carotid artery, it passes to the intrapleural space in the neck, where it branches off to the base of the heart (to the atria) and the hilum of the lung.

Sensory parts of the vagus nerve originate from the skin of the outer ear. They can cause a cough and nausea if they receive a certain stimulus (cotton bud). A few sensory parts originate in the epiglottis and the pharynx; proprioceptors originate in the muscles of the neck and pharynx and in chemoreceptors in the carotid glomus near the aortic arch. Further branches pass to the recurrent laryngeal nerve, which passes back to the laryngeal cartilage to supply the vocal folds. In addition, there are axons of viscerosensory receptors of thoracic and abdominal organs.

Additionally, parasympathetic fibers extend from the nuclei of the medulla to the lung and the heart. The pressure receptors at the carotid glomus contain fibers of the vagus nerve that are necessary for blood pressure regulation. The vagus gives rise to a network of branches around the esophagus to enter the abdomen at the esophageal hiatus.

The **glands of the gastrointestinal tract, the smooth musculature of the respiratory tract**, the stomach, the esophagus, the gallbladder, the small intestine, and most parts of the large intestine are supplied by the parasympathetic axons.

The skeletal muscles of the inner and outer neck are innervated by somatomotor neurons.

Function of the vagus nerve

Sensory functions include the following:

- Taste and sensation (touch, pain, temperature, etc.) in the epiglottis and the pharynx
- Blood pressure regulation
- Regulation of the oxygen and carbon dioxide content in the blood for the control of ventilation
- Sensation in visceral, thoracic, and abdominal organs

Somatomotor functions include the following:

- Swallowing
- Coughing
- Voice production

Parasympathetic functions include the following:

- Contraction and relaxation of the smooth musculature of the gastrointestinal tract
- Reduction of the heart rate
- Secretion of digestive juices

CN XI: Accessory Nerve

Quality and course

The accessory nerve is the **main motor, mixed CN, which emerges from the brainstem and the spinal cord.**

Cranial root:

The cranial root arises from the nuclei of the medulla oblongata. It passes through the jugular foramen and supplies **the musculature of the pharynx, the larynx, and the velum to enable the swallowing process.**

Spinal root:

The spinal root contains **mixed, but mainly motor, axons.** The motor axons pass through the foramen magnum and exit the jugular foramen together with the cranial fibers. Motor impulses are transmitted via the spinal root to the sternocleidomastoid muscle and the trapezius muscle, which **control the movement of the head.**

Sensory axons originate from the proprioceptors of the muscles. They supply the motor neurons and end in the medulla oblongata.

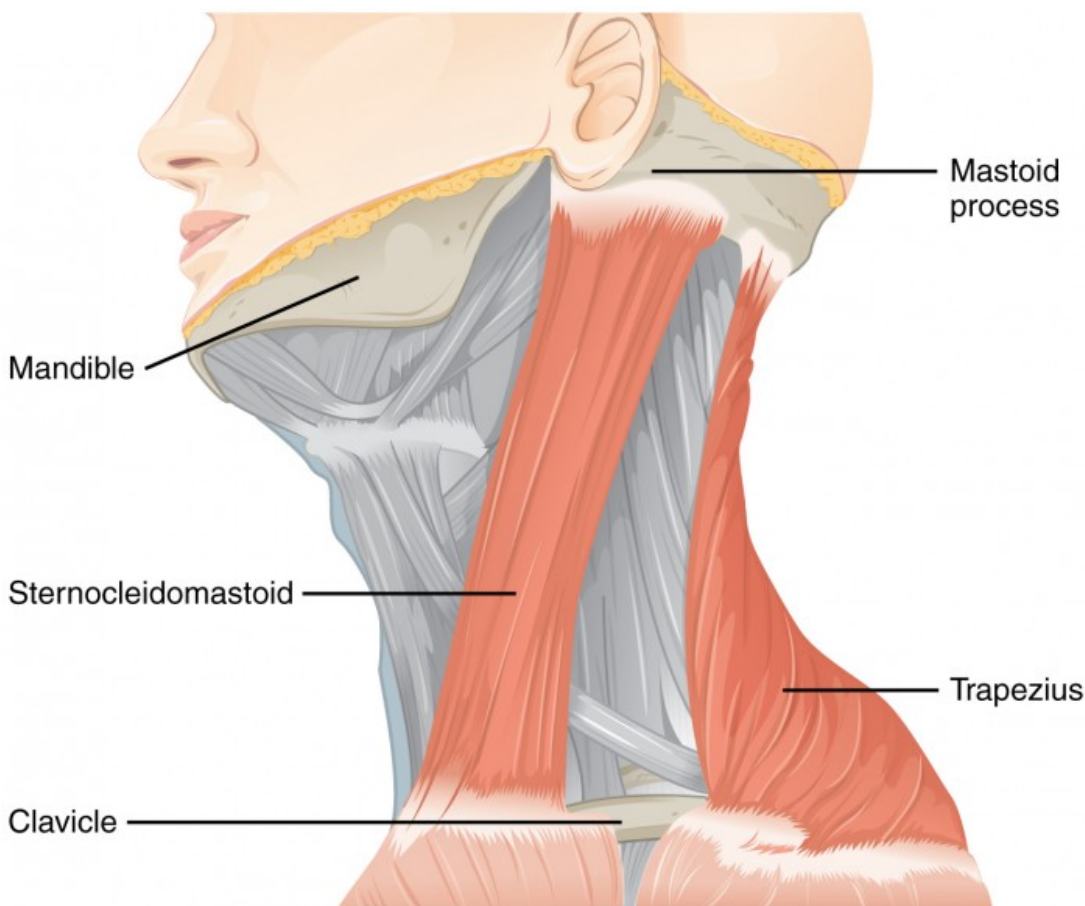


Image: 'Muscles Controlled by the Accessory Nerve' by Phil Schatz. License: [CC BY 4.0](https://creativecommons.org/licenses/by/4.0/).

Function of the accessory nerve

Sensory functions include the following:

- Proprioception

Somatomotor functions include the following:

- Innervation of the sternocleidomastoid muscle and the trapezius muscle to control the movement of the head and the shoulders
- Swallowing movement

CN XII: Hypoglossal Nerve

Quality and Course

The hypoglossal nerve is a **mixed CN with mainly motor functions**.

The somatomotor axons passing through the hypoglossal canal arise from a nucleus of the medulla oblongata. However, the sensory part consists of proprioceptor axons of the tongue muscles and ends in the medulla oblongata.

Function of the hypoglossal nerve

Somatomotor functions include the following:

- Innervation of tongue muscles
- Transmission of impulses for speaking and swallowing

Sensory functions include the following:

- Proprioception

Overview of the 12 CNs

CN	Function	Nuclei	Quality
I—olfactory nerve (smell)	Transmits signals from the olfactory organ (nose) to the brain	-	Somatosensory and afferent
II—optic nerve (vision)	Transmits visual signals from the retina to the brain	-	Somatosensory and afferent
III—oculomotor nerve (eye movement)	Controls four out of six outer eye muscles and the lifting muscle of the upper eyelid; accommodation; contraction of the pupil	Oculomotor nucleus, Edinger-Westphal nucleus	Somatomotor, vegetative, and efferent
IV—trochlear nerve (eye rotation/movement)	Controls the superior oblique muscle	Trochlear nucleus	Somatomotor and efferent

V—trigeminal nerve (facial sensation)	Subdivides into the eye nerve (ophthalmic nerve), upper jaw nerve (maxillary nerve), and lower jaw nerve (mandibular nerve); receives sensation from the facial area and transmits it to the brain; innervates the muscles of mastication	Spinal accessory nucleus, principal (sensory) nucleus of the trigeminal nerve, mesencephalic nucleus of the trigeminal nerve, spinal nucleus of the trigeminal nerve	Somatosensory, visceromotor, efferent, and afferent
VI—abducent nerve (eye movement)	Innervates the lateral eye muscle	Abducens nucleus	Somatomotor and efferent
VII—facial nerve (facial expression)	Provides motor innervation to the muscles of facial expression and the stapedius muscle; also transmits gustatory perception from the anterior two-thirds of the tongue; innervates all of the glands of the head, except the parotid gland	Nucleus of the facial nerve, superior salivary nucleus, and solitary nucleus	Visceromotor, vegetative, sensory, efferent, and afferent
VIII—vestibulocochlear nerve (hearing and balance)	Carries sensory information from the cochlea and the vestibular system	Cochlear nuclei and vestibular nuclei	Sensory and afferent
IX—glossopharyngeal nerve (oral sensation, taste, salivation)	Carries information from the posterior part of the tongue to the brain; innervates pharyngeal muscles; controls deglutition; innervates the parotid gland	Ambiguous nucleus, inferior salivary nucleus, nucleus of the solitary tract, and spinal nucleus of the trigeminal nerve	Sensory, visceromotor, vegetative, efferent, and afferent
X—vagus nerve ('wandering nerve')	Main nerve of the parasympathetic nervous system; regulates the activity of the internal organs	Ambiguous nucleus, dorsal nucleus of the vagus nerve, nucleus of the solitary tract, and spinal nucleus of the trigeminal nerve	Sensory, visceromotor, vegetative, efferent, and afferent
XI—accessory nerve (shoulder and head movement)	Controls the trapezius muscle and the sternocleidomastoid muscle	Ambiguous nucleus and spinal accessory nucleus	Somatomotor and efferent
XII—hypoglossal nerve (tongue movement; hypo = under, glossus = tongue)	Provides motor innervation of the muscles of the tongue	Hypoglossal nucleus	Somatomotor and efferent

Legal Note: Unless otherwise stated, all rights reserved by Lecturio GmbH. For further legal regulations see our [legal information page](#).

Notes